

Michael Ujiki and Benjamin D. Shogan

Introduction

Troubled by the high incidence of dysphagia in patients undergoing the Lortat-Jacob or Nissen antireflux procedure, the French surgeon André Toupet started experimenting on cadavers [1]. In 1963, after practice on 1,000 cadavers, yet performing the procedure on only four living patients, Toupet published his original description of a partial posterior fundoplication (PPF) that now bears his name [2] (Fig. 10.1). Received with widespread criticism by the surgical community, Toupet would never again publish his technique in a scientific journal and would perform a mere 20 hiatal hernia operations in his surgical career [1].

Various types of partial funduplications were described throughout the mid twentieth century, all having the goal of reducing postoperative dysphagia, gas bloat, and other side-effects which were common in patients having undergone a complete fundoplication. Initially, the partial wraps gained popularity more in the European countries, while the Nissen (complete 360° fundoplication) held international popularity. Although impossible to know exact numbers, it is generally thought that a Nissen procedure remains the most popular treatment for gastroesophageal reflux disease (GERD) worldwide with partial funduplications as a primary antireflux surgery, being much less common. Most surgeons perform partial funduplications only for specific indications such as for patients with severe esophageal motility disor-

ders or for achalasia following myotomy. However, there seems to be a trend in the literature suggesting that partial funduplications are being performed for an expanded list of indications. In this chapter, we review the indications, technique, and outcomes for the PPF.

Indications

A comprehensive description of the indications for antireflux surgery appears elsewhere in this textbook, and a review of PPF versus other types of fundoplication in specific situations will be discussed later in this chapter. Briefly, as with other types of funduplications, including the Nissen, PPF is indicated in patients with documented GERD or after reduction of a hiatal hernia (Table 10.1). Most surgeons give preference to a partial fundoplication over a complete wrap after a Heller myotomy performed for achalasia, or a myotomy and fundoplication after resection of an epiphrenic diverticulum. Additionally, patients whom have had a previous gastric resection or who have a tubular stomach may benefit from partial wraps due to lack of sufficient fundus to perform a full 360° wrap.

Patients with Esophageal Dysmotility

It is widely taught that partial fundoplication is superior to complete wraps in patients with severe esophageal dysmotility. To investigate, a surgical group in the UK stratified 127 reflux patients into effective and ineffective esophageal motility groups based on preoperative manometry, followed by randomization for either a Nissen or PPF [3]. At 1 year after surgery, patients who had a Nissen fundoplication had increased dysphagia scores and chest pain when eating compared to those who had a PPF. Interestingly, after the 1-year follow-up, they reported no difference in dysphagia, reflux related symptoms, or chest pain between the normal and abnormal motility patient groups, regardless of the type of fundoplication. Furthermore, they reported that there were

M. Ujiki, MD, FACS (✉)
Department of General Surgery, Minimally Invasive Surgery,
NorthShore Center for Simulation and Innovation, NorthShore
University HealthSystem, 2650 Ridge Avenue,
NCSI Suite B665, Evanston, IL 60201, USA
e-mail: mujiki@northshore.org

B.D. Shogan, MD
Department of Surgery, General Surgery Resident,
University of Chicago Medical Center,
5841 S. Maryland Avenue, Chicago, IL 60637, USA
e-mail: benjamin.shogan@uchospitals.edu

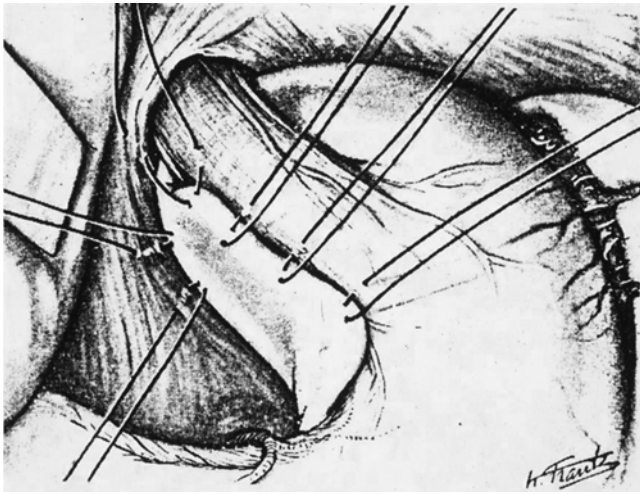


Fig. 10.1 Creation of Toupet fundoplication with key posterior gastropepy sutures and right fundoplication sutures to the esophagus. Left sided esophagopexy fundoplication sutures not shown

Table 10.1 Fundoplication indications

Indications for complete or partial fundoplication	GERD After reduction of hiatal hernia
Indications that favor partial fundoplication	Achalasia, after myotomy Epiphrenic diverticulum, after myotomy Previous gastric resection Tubular stomach

no significant differences in dysphagia rates between effective and ineffective motility groups who had a total fundoplication (28.6 vs. 16.7 %, $p=0.361$). Similarly, Shaw and colleagues conducted a randomized, prospective trial of 100 patients with 5-year follow-up, and reported that preoperative esophageal dysmotility had no influence over the outcome regardless of a complete or partial fundoplication [4]. Other randomized trials have demonstrated similar results [5–7]. Finally, Fein and Seyfried reviewed nine randomized trials comparing laparoscopic Nissen with various partial fundoplications. They concluded the preoperative non-specific esophageal motility disorders have no effect on the results of antireflux surgery no matter the type of fundoplication [8]. Although this goes against common surgical teaching, we conclude that the literature does not support an increased role of partial fundoplication in most cases of preoperative dysmotility (“tailored approach”).

Surgical Technique

The common surgical goals of any fundoplication are to augment the lower esophageal sphincter with a gastric collar, restoration of the angle of His and the abdominal segment of

Table 10.2 Key steps in partial posterior fundoplication

Technique key points
Optimal laparoscopic position is supine with steep reverse Trendelenburg
Circumferential hiatal dissection in a clockwise fashion starting with the right crus and avoiding the vagus nerves to maximize intra-abdominal esophageal length
Fundoplication after division of short gastric vessels
Posterior and anterior gastropexy

esophagus, and repair of a hiatal hernia if present (Table 10.2). When performed correctly, the fundoplication patient will have limited dysphagia, minimal reflux symptoms, and permanent repair. Many variations have been described since Toupet’s original description of an 180° posterior wrap. This original wrap, which did not close the hiatus or mobilize the fundus, had a high failure rate both from wrap herniation and incomplete reflux control. The “Toupet” was subsequently modified to make it more permanent and a better reflux barrier. Major variations included increasing the degree of fundic wrap and closing the hiatus to prevent mediastinal migration. Today the most common type of partial posterior wrap is a 270° to 340° wrap with posterior hiatal closure, which will be described below [9].

Open Verses Laparoscopic

Minimally invasive surgery has been described as the greatest surgical advance of the last century. Due to difficult hiatal exposure during a laparotomy, gastric fundoplication was an early candidate to benefit from laparoscopy. Since its introduction by Dallemagne et al. in 1991, the question of the safety and efficacy of laparoscopic fundoplication has been irrefutably answered. To date, at least 19 trials comparing open versus laparoscopic fundoplication have been performed, 12 of which were randomized-controlled trials and recently compiled into a systematic review and meta-analysis. The results clearly showed that patients whom had undergone laparoscopic fundoplication were discharged from the hospital ~2.5 days earlier, returned to normal activity 8 days earlier, and had a 65 % reduction in the relative odds of postoperative complications compared with patients having undergone an open technique [10]. On follow-up, either by questionnaire or by pH monitor, both cohorts had a similar decrease in GERD symptomatology. Importantly, despite a decreased complication rate and equal treatment failure rate, the laparoscopic cohort had a significantly higher incidence of repeat surgery, perhaps reflecting the patient’s willingness to undergo a better-tolerated operation rather than a higher absolute failure rate.

A few investigators have looked specifically at laparoscopic versus open PPF fundoplication [11]. In a prospective randomized trial of nearly 200 patients, a laparoscopic

approach decreased hospital length of stay and overall complication rate, despite having a similarly decreased patient-assessed symptom score on 1 and 3-year follow-up. Dissimilar to the above-mentioned meta-analysis, however, there were no differences between reoperation rates, although for the open cohort, the indication was most commonly incisional hernia, while for the laparoscopic group it was for recurrent disease.

Taken together, the literature supports laparoscopic fundoplication as a safe and effective alternative to an open technique and we recommend it in the majority of patients. Remaining indications for performing an open fundoplication include inexperience with laparoscopy, intra-operative complications that are unable to be repaired using laparoscopic measures, and patient preference. Some authorities recommend an open technique when performing a reoperation after a previous fundoplication, especially if the original operation was performed in an open fashion. Others have reported good results using laparoscopy on reoperation and thus this question is best left up to the surgeon and dependent on their laparoscopic experience.

Laparoscopic PPF

Preparation begins prior to the day of surgery. Patients with a profound esophageal motility disorder, such as achalasia, should be placed on a clear liquid diet 24 h prior to surgery. Good communication with the anesthesiologist is important to avoid a potentially lethal aspiration event as most patients with GERD or poor esophageal motility are at high-risk for aspiration and therefore rapid sequence induction and intubation is recommended.

Patient Position

The patient is positioned on the operating room table in supine position. The patient's arms can either be tucked or outstretched to $\sim 80^\circ$ and secured on padded arm boards. We prefer to abduct the legs on flat-padded split leg boards to minimize the possibility of neurovascular injury. The patient should be well secured in order to achieve steep reverse trendelenburg, which will help in displacing organs from the hiatus. The surgeon can either stand between the patient's legs, or on the patient's left depending on preference. When only one assistant is available, we find that it is best for the surgeon to stand on the patient's left with the first assistant in between the patient's legs (Fig. 10.2).

Laparoscopic Port Sites

The initial port site is placed 12 cm below the xiphoid process and 2.5 cm to the left of the midline using either an open or closed technique of entry as per surgeon preference (Fig. 10.3). It is important that this port not be placed too inferior or the mediastinum may be difficult to visualize. This initial port is typically a 10–12 mm for entry of a 10 mm

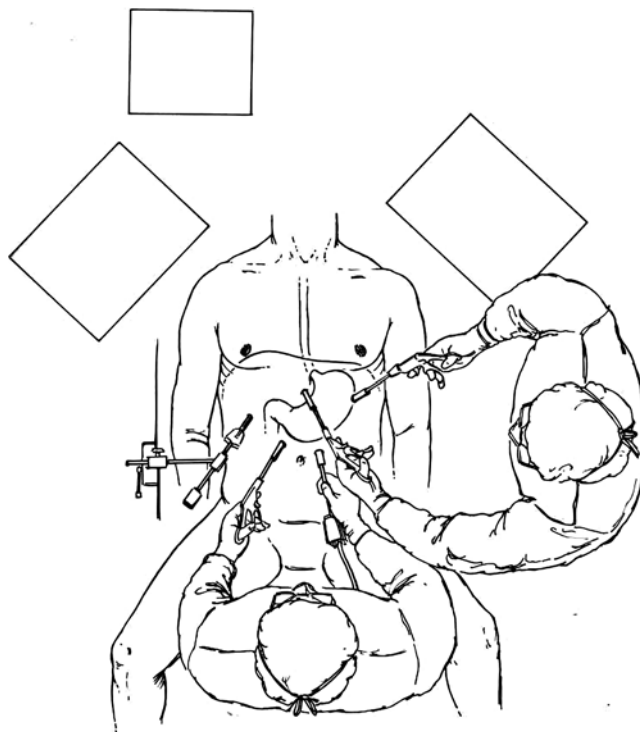


Fig. 10.2 Laparoscopic positioning

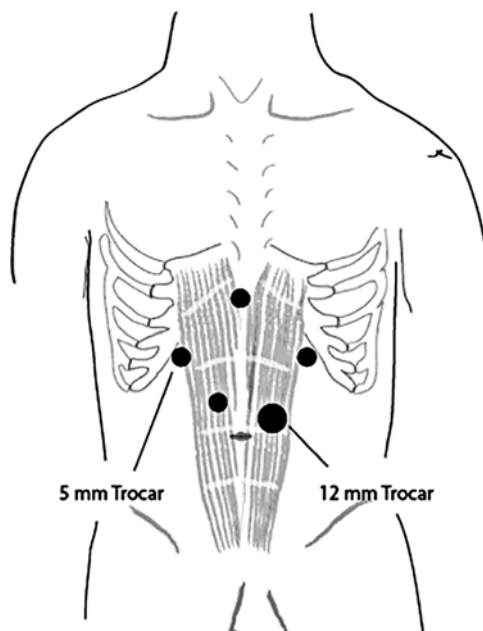


Fig. 10.3 Laparoscopic port site positioning

30–45° laparoscope. We prefer a 10 mm scope for optimal visualization. After entry, the abdomen is explored looking for iatrogenic injury and presence of intra-abdominal adhesions that would hinder subsequent port placement. A 5 mm port is then placed 15 cm from the xiphoid and 2–3 cm inferior

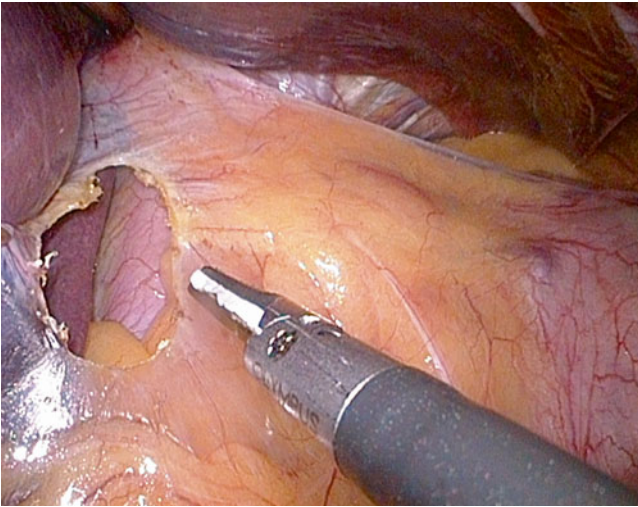


Fig. 10.4 Division of the gastrohepatic ligament

to the right costal margin for the liver retractor. The left lobe of the liver is retracted anteriorly using the preferred liver retractor of the surgeon and secured to the operating room table. A 5 mm port is then placed between the first two ports and used by the assistant to retract for the surgeon. With the liver retracted, a 5 mm port is placed just inferior to the xiphoid and will serve as the surgeon's left hand. Lastly, a 5 mm port is placed 10 cm from the xiphoid and 3 cm below the left costal margin for the surgeon's right hand.

Hiatal Dissection

Using an atraumatic grasper, the assistant surgeon grasps the anterior epigastric fat pad and retracts the stomach downward and towards the left lower quadrant. The surgeon divides the hepatogastric ligament along the edge of the caudate lobe, preserving the nerve of Latarjet, and any aberrant left hepatic arteries if present, using ultrasonic or bipolar shears (Fig. 10.4). If a giant paraesophageal hernia is present, it is often better to gain access to the mediastinum anteriorly in order to avoid structures, such as the left gastric artery, that may be herniated just inside the right crus. The right anterior phrenoesophageal ligament and peritoneum overlying the anterior abdominal esophagus is fully divided staying superficial in order to avoid injury to the anterior vagus and esophagus. Careful mediastinal dissection is then performed by sweeping the esophagus away from the right crus. At this point, it is important to identify the posterior vagus and sweep it towards the esophagus, often best achieved by the surgeon retracting the right crus laterally with his or her left hand (Fig. 10.5). The left hand can then elevate the anterior crus and the mediastinal dissection is continued circumferentially in a clockwise fashion until the left and right crural limbs are freed anteriorly and posteriorly. This mediastinal dissection is performed with a combi-

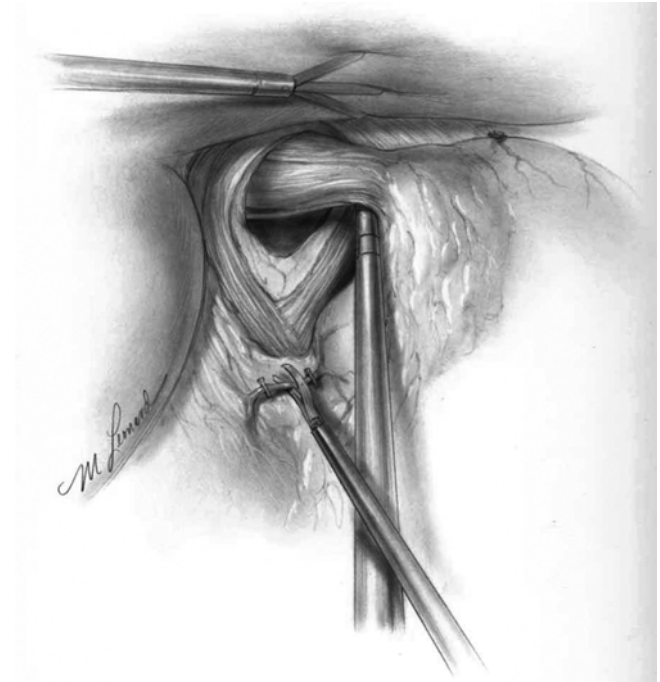


Fig. 10.5 Retrogastroesophageal junction dissection with sweep of vagus nerve anteriorly with the esophagus

nation of sharp and blunt dissection until 3–4 cm of tension-free intra-abdominal esophagus is freed. Meticulous attention is needed to avoid inadvertent vagal or esophageal injury. The hiatus is then closed posteriorly with interrupted permanent suture. Hiatal closure can be tight when repairing a large hiatal or paraesophageal hernia, or preferably somewhat lax when performing a fundoplication, particularly in a patient with a motility disorder such as achalasia.

Fundoplication

The short gastric vessels are ligated along the upper third of the gastric fundus (from the inferior pole of the spleen proximally, or approximately 10–15 cm inferior to the Angle of His) allowing free rotation of the gastric fundus without tension. A retroesophageal window is created and the posterior wall of the fundus is grasped and dragged behind the posterior vagus and posterior distal esophagus. A “shoeshine” maneuver is performed to confirm that no twisting of the esophagus is present (Fig. 10.6). If the fundus is grasped and pulled correctly, it should lie to the right of the esophagus without retracting back when let free. The assistant now grasps the gastric fundus retracting it towards midline, which in turn retracts the esophagus, exposing the posterior hiatus (Fig. 10.7). A posterior gastropexy is performed by suturing the posterior fundus to the inferior crus with one to three interrupted permanent sutures. A bougie is then placed carefully and under laparoscopic vision if desired. The size of the bougie will vary based on the diameter of the esophagus and

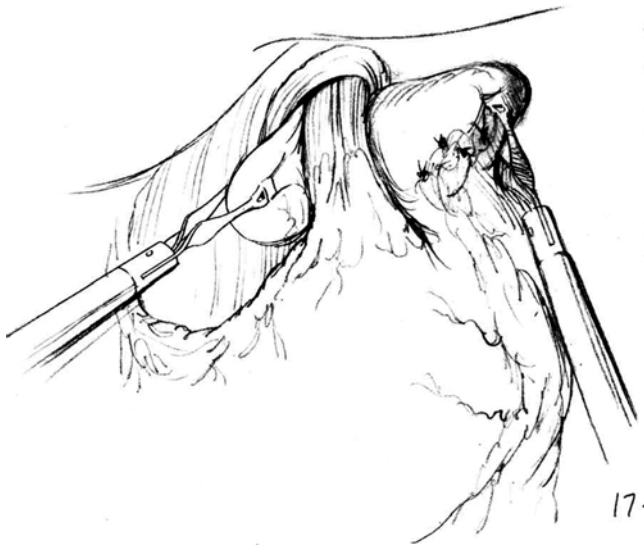

Fig. 10.6 “Shoe shine” maneuver

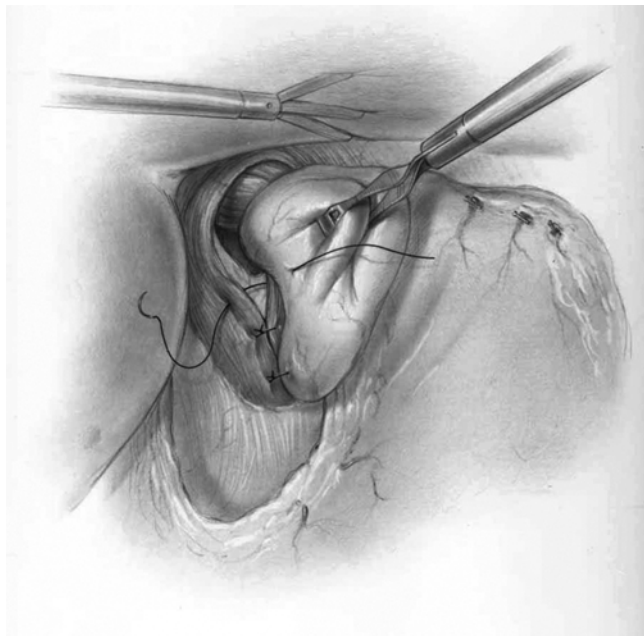


Fig. 10.7 Posterior gastropexy sutures with crural closure

whether or not a myotomy has been performed; with a myotomy, we tend to use a smaller bougie (48–52Fr), whereas without a myotomy, a larger size bougie (54–60Fr) can be placed based on visual estimation of the patient’s esophagus and degree of dysmotility or reflux. Two coronal stitches are placed at 10 and 2 o’clock securing the shoulders of the fundus to the diaphragmatic hiatus. Next, two to three interrupted sutures are placed from the esophagus to the left and right fundus (Fig. 10.8). If a myotomy has been performed, the edges of the fundus should be sutured to the muscle edges which will in turn splay the myotomy open.

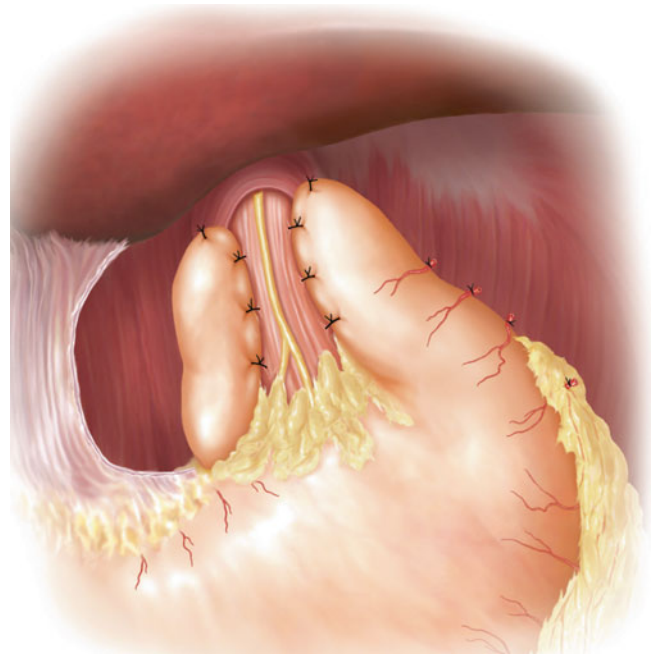


Fig. 10.8 Completed posterior partial fundoplication

Open PPF Technique

Patient Position

The patient is positioned on the operating room table in supine position, with their arms tucked. After intubation and induction of general anesthesia, a urinary catheter is placed and an upper midline incision is made from subxiphoid to supraumbilical. The surgeon may use any retraction system they prefer with the goal of optimal exposure by retraction of the xiphoid and inferior ribcage forward. As with any laparotomy, retraction is needed to separate the abdominal fascia and wound edges. Raising the head of the bed 20°–30° helps to cause the small intestine and omentum to fall inferiorly creating maximum hiatal exposure.

Technique

Hiatal dissection begins by retraction of the left lobe of the liver forward to expose the esophageal hiatus. At this point it may be necessary to divide the left triangular ligament of the liver. The phrenoesophageal ligament, comprising a superficial peritoneum and deeper fibrous layer is incised circumferentially around the esophagus to display the edges of the two hiatal pillars. Attention to detail is required during this dissection to prevent injury to the left and right vagal trunks that are found anteriorly and posteriorly respectively. Additionally, the surgeon must be meticulous during this dissection to avoid iatrogenic esophageal perforation.

When the distal esophagus is thoroughly freed from its surroundings, umbilical tape or a Penrose drain is placed behind and around the esophagus to retract it anteriorly

exposing the posterior hiatus. The stomach is retracted inferiorly to expose 5–6 cm of distal esophagus. The open fundoplication is performed in a similar fashion to the laparoscopic technique (see previous).

In the original description, Toupet did not include a hiatal repair or closure, but if the hiatal orifice remains too large after the technique described above is performed, we recommend placing sutures across the hiatus to prevent slippage of the fundus.

Robotic Fundoplication

Robotic surgery is the newest commonly performed minimally invasive procedure and has been increasingly utilized in the urologic and gynecologic literature. Currently, no clear indications exist in general surgery for robotic surgery. The precise manipulations and improved dexterity afforded by the use of the robot have intrigued general surgeons and have been applied to a diverse range of operations ranging from pelvic dissections to thyroid surgery.

Due to the complexity of performing a laparoscopic fundoplication, this procedure is an easy target for a novel technique. In a pilot study of six patients undergoing robot-assisted laparoscopic PPF, Wykypiel and colleagues reported no intra-operative complications, and no reflux symptoms or dysphagia on 6-month follow-up [12]. Since this early experience, seven randomized trials have been performed comparing robotic versus laparoscopic fundoplication. A recent meta-analysis and systematic review of these randomized trials confirmed no significant difference between the robotic group and laparoscopic group for hospital stay, operative complications, postoperative dysphagia, or postoperative GERD symptom relief, although there was significant increase in operative time for those patients in the robotic cohort (weighted mean difference=4.15; 95 % CI=1.93–6.38; $p<0.001$) [13]. As the authors suggest, although these results are limited by small sample sizes and short follow-up, it appears that robotic surgery provides no additional benefit over laparoscopic surgery and is associated with increased operative time and cost.

Postoperative Management

After the operation is completed, the patient is brought to the recovery room, and then admitted to the surgical floor. Postoperatively, the patient takes nothing per mouth and is started on intravenous fluids and narcotics/anti-emetics as needed. For patients whom had undergone laparoscopic surgery their diet can usually be advanced later the day of surgery when post anesthesia nausea has resolved. Typically, the diet is advanced to a liquid diet for one meal, and then pureed diet for 2 weeks. We then advance from pureed to a

soft diet for several days until returning to a general diet. Generally, laparoscopic patients are discharged on postoperative day 1, while patients having undergone an open technique require 2–3 more days of in-hospital recovery. We advise patients to avoid retching by taking anti-emetics at the first sign of nausea. Though most important in the first 6 months after surgery, we recommend life-long avoidance by pre-emptive antiemetic use.

Outcomes

Outcomes after PPF vary depending upon the indication. Here, we review the relevant outcome literature for the most common indications, and compare PPF to Nissen and Dor (partial anterior) fundoplication.

GERD

Patient outcomes after PPF for GERD are excellent. In both the short term and in up to 10-year follow-up, laparoscopic PPF significantly improved the quality of life and decreased GERD symptoms (heartburn and regurgitation), with only ~10 % reporting subjective recurrence of reflux exposure [14]. In an extremely long-term study, open PPF has shown to have successful control of GERD symptoms after two decades of follow-up [15]. Additionally, patients appear to be happy with their choice of undergoing surgery, with greater than 85 % reporting that they would have repeat surgery or recommend fundoplication to a friend [4, 16].

Complete or Partial

Nissen fundoplication has been extensively compared to PPF. Laparoscopic Nissen fundoplication (NF) is frequently cited as the most common operation performed for GERD. Despite generally excellent long-term outcomes with laparoscopic NF, severe or persistent dysphagia can occur in 3–43 % of patients, as well as bloating and early satiety [17–19]. These unwanted side-effects are likely due to the outflow resistance from a circumferential wrap and therefore partial wraps have been proposed to provide less long-term postoperative dysphagia due to the “hinge effect” of leaving a part of the esophagus uncovered while still maintaining similar GERD symptomatic relief. Early outcome comparisons between NF and PPF have failed to confirm this advantage and instead showed that PPF was associated with increased heartburn, increased use of proton pump inhibitors, and decreased quality of life scores [20–22]. Conversely, in a recent prospective trial, 100 patients were randomized to either laparoscopic NF or laparoscopic PPF. Despite an elevated average wrap pressure in the NF group (15.2 vs. 12.0 mmHg), there was no difference in the incidence of dysphagia, GERD symptom relief, or quality

of life after an average follow-up of ~55 months [4]. Similarly, other prospective randomized trials showed equal improvement in postoperative quality of life and GERD symptomatic relief, although dysphagia and inability to belch were more common after NF [23, 24]. To provide a more definitive answer, recently two independent systematic reviews and meta-analysis have been performed [25, 26]. Both groups of authors concluded that laparoscopic PPF reduced postoperative dysphagia rates, reoperation rates, and prevalence of gas-related symptoms with similar patient satisfaction and reflux control compared to laparoscopic NF. The authors did comment that the low quality of some of the included randomized control trials might bias the reported results. Taken together we conclude, as others have, that laparoscopic PPF is a safe and viable alternative to laparoscopic NF with likely lower rates of adverse consequences and reoperation rates in select patients.

Anterior or Posterior

Comparison between partial anterior fundoplication (AF) and PPF has also been studied. In a randomized-controlled single institution trial, 95 patients were randomized to PPF and AF. After 1 year of follow-up, patients who had undergone a PPF had better control of GERD symptoms although they exhibited increased dysphagia and increased acid exposure than with an anterior wrap [27]. Similarly, in a different randomized clinical trial with longer follow-up (65 months), laparoscopic PPF continued to provide better reflux symptom control and decreased reoperation rates, and at 5 years did not come at the expense of increased dysphagia [28]. Very recently this subject was addressed by a systematic review and meta-analysis of all randomized control trials comparing AF, NF, and PPF [29]. After review of 11 trials, they found posterior fundoplication to be associated with increased GERD symptom relief and decreased reoperation rate compared to anterior wraps. In the short term, less severe dysphagia is seen in patients who undergo an anterior wrap, but dysphagia scores become equivalent in the long term. This study did not include a subgroup analysis of AF vs. PPF because of the results of the previous systematic reviews showing equivalent reflux control between complete posterior and partial posterior, and thus they ultimately conclude that of the three operations, posterior partial is the operation of choice for GERD.

Achalasia

Achalasia is characterized by failure of relaxation of the distal esophageal sphincter. Partial fundoplication has classically been used in the treatment of achalasia to rebuild the reflux barrier after esophageal myotomy. The role of fundoplication after myotomy continues to be debated with some investigations showing no patient benefit, while others show that adding a fundoplication decreases postoperative GERD

[30–32]. Recently, a systematic review and meta-analysis clearly showed the benefit of some type of a fundoplication after myotomy. This review of over 7,000 patients showed that laparoscopic myotomy in combination with fundoplication provided better symptom relief (90 %) than any other surgical technique, and significantly reduced the incidence of postoperative GERD (31.5 % without fundoplication versus 8.8 % with fundoplication, $p=0.003$) [33]. Given this benefit and in agreement with other groups, we recommend the routine use of fundoplication after myotomy [34, 35].

The optimal type of fundoplication to combine with myotomy is less clear and no consensus exists, but all types of surgical funduplications have been proposed. It has been theorized that because there is aperistalsis of the distal esophagus in patients with achalasia, a complete fundoplication may impede esophageal emptying causing regurgitation and dysphagia. In a large, long-term randomized trial, Rebecchi and colleagues showed this to be true [36]. In their study, 138 patients were randomized to AF or NF fundoplication. After a mean follow-up of 152 months, they reported that the incidence of dysphagia was 15 % in the NF cohort, while it was 2.8 % in the AF, although control of reflux was equivalent ($p<0.001$). Other groups have confirmed an unacceptably high rate of postoperative dysphagia with a complete fundoplication [37, 38]. Despite some centers reporting adequate outcomes with NF, the general agreement is that partial funduplications are superior to full fundoplication after myotomy [39, 40].

Few studies have compared AF to PPF after myotomy, although as outlined above, PPF appears to be the superior partial fundoplication for GERD. Very recently, in one of the only studies of its kind, this was studied during a multicenter, prospective, randomized trial [41]. Sixty patients were randomized to either AF or PPF and followed for 1 year. Dysphagia and regurgitation scores, as well as postoperative quality of life scores did not significantly differ between the two surgical procedures. Abnormal reflux was more present in the AF cohort (41.7 %) compared to the PPF cohort (21 %) but this difference failed to reach significance ($p=0.152$). Of note, the authors did caution interpretation of these results given the small sample size and significant amount of patients lost to follow-up. It should be noted that some groups recommend AF over PPF given less disruption of hiatal anatomy and coverage and reinforcement of the esophageal mucosa with the fundus, although there is limited evidence to confirm or refute this [41]. Together, given the current literature and lack of long-term outcome data, anterior or posterior partial fundoplication after myotomy is the surgeon's preference.

Epiphrenic Diverticulum

Epiphrenic diverticulum is a rare esophageal disorder characterized by out-pouchings of the distal 10 cm of esophagus.

Patients often present with dysphagia, odynophagia, chest pain, or regurgitation, although an increasing number of patients are diagnosed incidentally having undergone radiographic or endoscopic evaluation for a different indication. While there is agreement that operative intervention is indicated in the case of severe symptoms, some authors advise surgery in asymptomatic patients to avoid aspiration risk [42]. When surgery is performed, the technique remains up for debate and open, laparoscopic, transabdominal, and transthoracic approaches have been described. Most authors advocate the use of diverticulectomy and myotomy rather than diverticulectomy alone given the link between diverticula and primary spastic esophageal motility disorders [43, 44]. Unfortunately, there is no data comparing dysphagia and GERD in patients having undergone myotomy with and without fundoplication for epiphrenic diverticulum. In a retrospective review, similar to the achalasia literature, the addition of fundoplication was shown to be associated with decreased postoperative heartburn [45]. Different than for achalasia, the treatment of diverticulum requires diverticulectomy and thus creation of a distal esophageal suture line. Albeit only 13 patients were included in their study, Del Genio et al. [44] showed that the addition of a NF increased dysphagia and resulted in a 23.1 % leak rate, possibly due to the increased esophageal pressure that a NF creates. On the other hand, Klaus et al. [45] reported excellent symptom control and no leaks in patients having undergone a PPF. Similar results have been seen with an AF or Belsey Mark IV fundoplication [43]. Given the rarity of these diseases further studies will be needed to provide a definitive answer on the optimal type of fundoplication, but given the current literature it appears that either type of partial fundoplication is warranted.

Perioperative Complications

As with all surgical procedures, fundoplication is prone to postoperative complications. Fortunately the risk of catastrophic adverse consequences is low. As described by Greenstein and Hunter [46], postoperative events can be divided into early and late complications. Early complications are rare and include ileus (<5 %), pneumothorax (1–3 %), wrap herniation (<1 %), gastric or esophageal perforation (<1 %), hemorrhage (<1 %), wound infection (<0.5 %), and mortality (<0.2 %). Importantly, Tan and colleagues noted a significantly increased rate of postoperative complications in patients undergoing PPF when performing their systematic review and meta-analysis of all randomized-controlled trials comparing NF and PPF [26]. In most of the PPF arms of the 7 included randomized trials, there were commonly 1–3 patients who had a postoperative complication including hemorrhage, pneumothorax, or plural effu-

sion, while the NF cohort commonly reported a lack of postoperative adverse events. In each of the individual studies the complication rate between the two groups did not reach significance, but when pooled for their meta-analysis the difference was significant. The authors hypothesized that because the distal esophagus has no serosal layer, suturing the fundus directly to esophagus and diaphragm during a PPF could increase the risk of perforation.

Late complications, including dysphagia, gas-related symptoms, and GERD symptoms are more frequent and may be related to the type of fundoplication as described earlier in the text. Presentation and management of the more serious complications are worth discussing in detail:

Perforation

Likely the most feared complication after esophageal or gastric surgery is perforation or anastomotic leak, as it is well known to be associated with increased morbidity and mortality. Perforation may occur at anytime during the dissection, during use of the bougie or endoscope, during suture plication of the fundus, or may appear late as a consequence of ischemia or electrocautery injury unrecognized intraoperatively. If perforation is found during the operation, it should be repaired primarily with coverage of the suture line with the gastric fundus when possible. We feel that the routine use of closed suction drains for this type of repair is unwarranted. A perforation or leakage from a suture line found postoperatively is more troubling and is usually diagnosed by fever, leukocytosis, and possible abdominal peritoneal signs, leading to imaging and demonstration of extravasation of contrast. In this situation, treatment can include reoperation in the case of an early leak, or endoscopic stenting, antibiotic therapy, and drainage in the case of leaks later than 24–48 h.

Herniation

Herniation can occur in the immediate postoperative period when the gastric fundus herniates through the hiatus. Fortunately, acute herniation is rare, thought to occur in <1 % of patients, and is characterized by epigastric pain and tachycardia, and confirmed by a contrast study. Early herniation requires immediate reoperation, reduction, and repeat crural closure. Late herniation, which occurs years or decades after the original operation, is addressed in other parts of this text.

Dysphagia

Dysphagia is one of the more frustrating complications after antireflux surgery. Symptoms of dysphagia such as regurgitation,

inability to swallow, or the feeling of food getting stuck in the patient's throat, are common in the early postoperative period, but symptoms will only persist after the first few weeks in less than 10 % of patients [47]. In this early period, symptoms are thought to arise from esophageal or gastric edema and therefore patients are advised to eat small, soft, and frequent meals, which over time will resolve their symptoms. Fortunately, only 3 % of patients will report continued dysphagia after 6 months, and this incidence appears to be lower with PPF versus a complete NF [26]. As a guideline, patients who have persistent dysphagia for more than 6–12 weeks should undergo barium swallow to assess esophageal motility and wrap placement. In patients with continued dysphagia and abnormal passage of barium through the gastroesophageal junction, we recommend endoscopic dilation with successive dilations as needed. With a PPF, to get to the point of dilation is rarely required, and when it is performed it is likely curative [48]. Patients with chronic dysphagia, severe symptoms, or symptoms arising from herniation may require reoperation.

Summary

Despite initial criticism when it was first presented in André Toupet in the early 1960s, the PPF has now gained widespread popularity. PPF is indicated in patients with documented GERD or after reduction of a hiatal hernia, and is favorable over complete fundoplication in patients who have undergone a myotomy for treatment of achalasia or epiphrenic diverticulum. Surprisingly, the literature does not support an increased role of partial fundoplication in cases of preoperative dysmotility. For all indications, outcomes after PPF are excellent with the majority of patients reporting increased quality of life, decreased reflux related symptoms, and minimal, if any, dysphagia. Finally, the advent of laparoscopic PPF has afforded patients a safe procedure with a shorter hospital stay.

References

- Katkhouda N, Khalil MR, Manhas S, Grant S, Velmahos GC, Umbach TW, et al. André Toupet: surgeon technician par excellence. *Ann Surg.* 2002;235:591–9.
- Toupet A. La technique d'oesophagoplastie avec phrenogastropexie appliquée dans la cure radicale des hernies hiatales et comme complément de l'opération de Heller dans les cardiopasmes. *Mem Acad Chir.* 1963;89:394–9.
- Booth MI, Stratford J, Jones L, Dehn TC. Randomized clinical trial of laparoscopic total (Nissen) versus posterior partial (Toupet) fundoplication for gastro-oesophageal reflux disease based on preoperative oesophageal manometry. *Br J Surg.* 2008;95:57–63.
- Shaw JM, Bormman PC, Callanan MD, Beckingham IJ, Metz DC. Long-term outcome of laparoscopic Nissen and laparoscopic Toupet fundoplication for gastroesophageal reflux disease: a prospective, randomized trial. *Surg Endosc.* 2010;24:924–32.
- Broeders JA, Roks DJ, Ahmed Ali U, Draaisma WA, Smout AJ, Hazebroek EJ. Laparoscopic anterior versus posterior fundoplication for gastroesophageal reflux disease: systematic review and meta-analysis of randomized clinical trials. *Ann Surg.* 2011;254:39–47.
- Chrysos E, Tsiaoussis J, Zoras OJ, Athanasakis E, Mantides A, Katsamouris A, et al. Laparoscopic surgery for gastroesophageal reflux disease patients with impaired esophageal peristalsis: total or partial fundoplication? *J Am Coll Surg.* 2003;197:8–15.
- Rydberg L, Ruth M, Abrahamsson H, Lundell L. Tailoring antireflux surgery: a randomized clinical trial. *World J Surg.* 1999;23:612–8.
- Fein M, Seyfried F. Is there a role for anything other than a Nissen's operation? *J Gastrointest Surg.* 2010;14:S67–74.
- Swanström LL. Laparoscopic Toupet fundoplication. In: Patterson GA, Pearson FG, Cooper JD, Deslauriers J, Rice TW, Luketich JD, et al., editors. *Pearson's thoracic and esophageal surgery.* Philadelphia: Elsevier Health Sciences; 2008.
- Peters MJ, Mukhtar A, Yunus RM, Khan S, Pappalardo J, Memon B, et al. Meta-analysis of randomized clinical trials comparing open and laparoscopic anti-reflux surgery. *Am J Gastroenterol.* 2009;104:1548–61.
- Hakanson BS, Thor KB, Thorell A, Ljungqvist O. Open vs laparoscopic partial posterior fundoplication a prospective randomized trial. *Surg Endosc.* 2007;21:289–98.
- Wykypiel H, Wetscher GJ, Klaus A, Schmid T, Gadenstaetter M, Bodner J, et al. Robot-assisted laparoscopic partial posterior fundoplication with the DaVinci system: initial experiences and technical aspects. *Langenbecks Arch Surg.* 2003;387:411–6.
- Markar SR, Karthikesalingham AP, Hagen ME, Talamini M, Horgan S, Wagner OJ. Robotic vs laparoscopic Nissen fundoplication for gastro-oesophageal reflux disease: systematic review and meta-analysis. *Int J Med Robot.* 2010;6:125–31.
- Kamolz T, Granderath FA, Bammer T, Wykypiel Jr H, Pointer R. "Floppy" Nissen vs. Toupet laparoscopic fundoplication: quality of life assessment in a 5-year follow-up (part 2). *Endoscopy.* 2002;34:917–22.
- Mardani J, Lundell L, Engstrom C. Total or posterior partial fundoplication in the treatment of GERD: results of a randomized trial after 2 decades of follow-up. *Ann Surg.* 2011;253:875–8.
- Sgromo B, Irvine LA, Cushieri A, Shimi SM. Long-term comparative outcome between laparoscopic total Nissen and Toupet fundoplication: symptomatic relief, patient satisfaction, and quality of life. *Surg Endosc.* 2008;22:1048–53.
- Anvari M, Allen CJ. Prospective evaluation of dysphagia before and after laparoscopic Nissen fundoplication without routine division of short gastrics. *Surg Laparosc Endosc.* 1996;6:424–9.
- Perdikis G, Hinder RA, Lund RJ, Raiser F, Katada N. Laparoscopic Nissen fundoplication: where do we stand? *Surg Laparosc Endosc.* 1997;7:17–21.
- Sato K, Awad ZT, Filipi CJ, Selima MA, Cummings JE, Fenton SJ, et al. Causes of long-term dysphagia after laparoscopic Nissen fundoplication. *JLS.* 2002;6:35–40.
- Farrell TM, Archer SB, Galloway KD, Branum GD, Smith CD, Hunter JG. Heartburn is more likely to recur after Toupet fundoplication than Nissen fundoplication. *Am Surg.* 2000;66:229–36.
- Fein M, Bueter M, Thalheimer A, Pachmayr V, Heimbucher J, Freys SM, et al. Ten-year outcome of laparoscopic antireflux surgery. *J Gastrointest Surg.* 2008;12:1893–9.
- Fernando HC, Lucketich JD, Christie NA, Ikramuddin S, Schauer PR. Outcomes of laparoscopic Toupet compared to laparoscopic Nissen fundoplication. *Surg Endosc.* 2002;16:905–8.
- Broeders JA, Bredenoord AJ, Hazebroek EJ, Broeders IA, Gooszen HG, Smout AJ. Reflux and belching after 270 degrees versus 360 degree laparoscopic posterior fundoplication. *Ann Surg.* 2012;255:59–65.

24. Koch OO, Kaindlstorfer A, Antoniou SA, Asche KU, Granderath FA, Pointer R. Laparoscopic Nissen versus Toupet fundoplication: objective and subjective results of a prospective randomized trial. *Surg Endosc.* 2012;26:413–22.
25. Broeders JA, Broeders JL, Mauritz FA, Ahmed Ali U, Draaisma WA, Ruurda JP, et al. Systematic review and meta-analysis of laparoscopic Nissen (posterior total) versus Toupet (posterior partial) fundoplication for gastro-oesophageal reflux disease. *Br J Surg.* 2010;97:1318–30.
26. Tan G, Yang Z, Wang Z. Meta-analysis of laparoscopic total (Nissen) versus posterior (Toupet) fundoplication for gastroesophageal reflux disease based on randomized clinical trials. *ANZ J Surg.* 2011;81:246–52.
27. Hagedorn C, Jönson C, Lönroth H, Ruth M, Thune A, Lundell L. Efficacy of an anterior as compared to a posterior laparoscopic partial fundoplication. Results of a randomized controlled clinical trial. *Ann Surg.* 2003;238:189–96.
28. Engstrom C, Lönroth H, Mardani J, Lundell L. An anterior or posterior approach to partial fundoplication? Long term results of a randomized trial. *World J Surg.* 2007;31:1221–5.
29. Broeders JA, Sportel IG, Jamieson GG, Nijjar RS, Granchi N, Myers JC, et al. Impact of ineffective oesophageal motility and wrap type on dysphagia after laparoscopic fundoplication. *Br J Surg.* 2011;98:1414–21.
30. Burpee SE, Mamazza J, Schlachta CM, Bendavid Y, Klein L, Moloo H, et al. Objective analysis of gastroesophageal reflux after laparoscopic Heller myotomy: an antireflux procedure is required. *Surg Endosc.* 2005;19:9–14.
31. Lyass S, Thoman D, Steiner JP, Phillips E. Current status of an antireflux procedure in laparoscopic Heller myotomy. *Surg Endosc.* 2003;17:554–8.
32. Wang PC, Sharp KW, Holzman MD, Clements RH, Holcomb GW, Richards WO. The outcome of laparoscopic Heller myotomy without antireflux procedure in patients with achalasia. *Am Surg.* 1998;64:515–20.
33. Campos GM, Vittinghoff E, Rabl C, Takata M, Gadenstatter M, Lin F, et al. Endoscopic and surgical treatments for achalasia: a systematic review and meta-analysis. *Ann Surg.* 2009;249:45–57.
34. Eckardt AJ, Eckardt VF. Current clinical approaches to achalasia. *WJG.* 2009;15:3969–75.
35. Stefanidis D, Richardson W, Farrell TM, Kohn GP, Augenstein V, Fanelli RD. SAGES guidelines for the surgical treatment of esophageal achalasia. *Surg Endosc.* 2012;26:296–311.
36. Rebecchi F, Giaccone C, Farinella E, Campaci R, Morino M. Randomized controlled trial of laparoscopic Heller Myotomy plus Dor Fundoplication versus Nissen Fundoplication for achalasia: long-term results. *Ann Surg.* 2008;248:1023–30.
37. Topart P, Deschamps C, Taillefer P, Duranceau A. Longterm effect of total fundoplication on the myotomized esophagus. *Ann Thorac Surg.* 1992;54:1046–51.
38. Chen LQ, Chugtai T, Sideris L, Nastos D, Taillefer R, Ferraro P, et al. Long-term effects of myotomy and partial fundoplication for esophageal achalasia. *Dis Esophagus.* 2002;15:171–9.
39. Falkenback D, Johansson J, Oberg S, Kjelin A, Wenner J, Zilling T, et al. Heller's esophagomyotomy with or without a 360 degrees floppy Nissen fundoplication for achalasia: long-term results from a prospective, randomized trial. *Dis Esophagus.* 2003;16:284–90.
40. Rossetti G, Bruscianno L, Amato G, Maffettone V, Napolitano V, Russo G, et al. A total fundoplication is not an obstacle to esophageal emptying after Heller myotomy for achalasia: results of a long term follow-up. *Ann Surg.* 2005;241:614–21.
41. Rawling A, Soper NJ, Oelschlager B, Swanstrom L, Matthews BD, Pellegrini C, et al. Laparoscopic Dor versus Toupet fundoplication following Heller myotomy for achalasia: results of a multicenter, prospective, randomized-controlled trial. *Surg Endosc.* 2012;26:18–26.
42. Altorki N, Sunagawa M, Skinner D. Thoracic esophageal diverticula. Why is the operation necessary? *J Thorac Cardiovasc Surg.* 1993;105:260–4.
43. Nehra D, Lord RV, Demeester TR, Theisen J, Peters JH, Crookes P, et al. Physiologic basis for the treatment of epiphrenic diverticulum. *Ann Surg.* 2002;235:346–54.
44. Del Genio A, Rossetti G, Maffettone V, Renzi A, Bruscianno L, Limongelli P, et al. Laparoscopic approach in the treatment of epiphrenic diverticula: long-term results. *Surg Endosc.* 2004;18:741–5.
45. Klaus A, Hinder RA, Swain J, Achem SR. Management of epiphrenic diverticula. *J Gastrointest Surg.* 2003;7:906–11.
46. Greenstein AJ, Hunter JG. Antireflux surgery in GERD. In: Tichansky DS, Morton J, Jones DB, editors. *The SAGES manual of quality, outcomes, and patient safety.* New York: Springer; 2012.
47. Wills VL, Hunt DR. Dysphagia after antireflux surgery. *Br J Surg.* 2001;88:486–99.
48. Almond LM, Wadley MS. A 5-year prospective review of posterior partial fundoplication in the management of gastroesophageal reflux disease. *Int J Surg.* 2010;8:239–42.